

# INTRAMEDULLARY LIMB-LENGTHENING

## Lessons Learned

Christopher A. Iobst, MD

*Investigation performed at the  
Department of Orthopedic Surgery,  
Nationwide Children's Hospital,  
Columbus, Ohio*

### Abstract

» With the use of blocking screws, acute deformity corrections can be combined with intramedullary limb-lengthening.

» Tibial lengthening with an intramedullary nail requires a longer latency period and a gentle rate and rhythm compared with tibial lengthening with an external fixator.

» Preparatory surgery is necessary to stabilize the adjacent joints before performing intramedullary limb-lengthening in patients with congenital limb-length discrepancy.

**I**ntramedullary limb-lengthening has become increasingly popular as a method of long-bone distraction osteogenesis over the past 5 years. This technique allows patients to avoid the inconvenience, discomfort, and pin-site infection risk associated with bone lengthening with an external fixator. While intramedullary lengthening is not a new concept, previous devices had issues with rate control, pain management, and bone formation<sup>1-6</sup>. Currently available implants, however, have demonstrated accuracy, dependable rate control, and reliable regenerate bone formation<sup>7-12</sup>. In addition, patients display increased comfort, satisfaction, and range of motion during lengthening with intramedullary devices as compared with external fixators<sup>13,14</sup>. This review article will outline technique tips and lessons learned from using current intramedullary lengthening devices.

### Expanded Indications

From a technical standpoint, intramedullary lengthening nails are only designed to distract or compress long-bone segments. The nails do not have any inherent capacity to accomplish deformity correction in the coronal, rotational, or sagittal

planes. Initially, these devices were only used in patients who required straight lengthening. However, as the experience with these nails increased over time, the indications for their use expanded.

Fixator-assisted nailing is a well-described concept that has been utilized for the accurate correction of long-bone deformities<sup>15</sup>. Combining this technique with intramedullary lengthening nails and blocking screws has substantially expanded the applications for the use of these implants (Fig. 1-A). Multiple studies have demonstrated that acute deformity correction followed by gradual lengthening can be performed safely, accurately, and reliably<sup>16-18</sup>. This breakthrough in surgical planning now allows many patients to have simultaneous correction of deformity and limb-length discrepancy without the need for an external fixator postoperatively. As an alternative to the fixator-assisted method, Baumgart described the correction of deformity with use of the reverse planning technique<sup>19</sup>. With that method, which involves a detailed preoperative plan, deformity correction can be achieved with use of straight reamers along a predetermined path in the distal femoral segment. The new medullary canal that is created in the distal segment is realigned

**Disclosure:** The authors indicated that no external funding was received for any aspect of this work. On the **Disclosure of Potential Conflicts of Interest** form, which is provided with the online version of the article, the author checked "yes" to indicate that he had a relevant financial relationship in the biomedical arena outside the submitted work (<http://links.lww.com/JBJSREV/A502>).

COPYRIGHT © 2019 BY THE  
JOURNAL OF BONE AND JOINT  
SURGERY, INCORPORATED

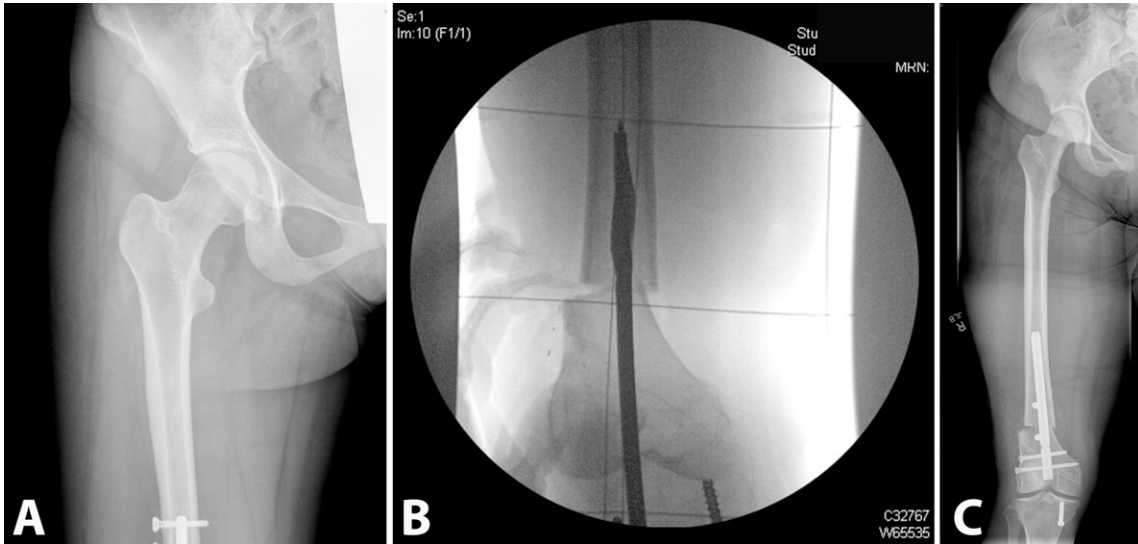


Fig. 1

**Fig. 1-A** Radiograph made after restoration of a neutral mechanical axis via an acute correction of a preoperative valgus deformity with a retrograde femoral nail and blocking screws. A temporary, intraoperative external fixator was used to obtain the correction, and the nail was inserted to maintain the correction. The limb-length discrepancy was corrected gradually with use of the intramedullary lengthening nail. **Figs. 1-B and 1-C** Radiographs demonstrating acute correction with use of the reverse planning method. The preoperative plan demonstrates the position of the guidewire (**Fig. 1-B**) and entry reamer necessary to achieve the desired correction without the use of an intraoperative external fixator (**Fig. 1-C**).

with the existing canal of the proximal segment, which automatically corrects the alignment (Figs. 1-B and 1-C).

As experience with the devices has increased, there has also been an expansion of the list of etiologies that can be successfully treated with this method. In

addition to the more common causes of limb-length discrepancy (posttraumatic, post-infectious, and congenital), patients with osteogenesis imperfecta, Ollier disease, oncological sequelae, bone cysts, and fibrous dysplasia have been managed with lengthening and deformity

correction without the need for an external fixator<sup>20-24</sup> (Figs. 2-A, 2-B, and 2-C).

Although intramedullary lengthening nails were intended for use in the femur and tibia, humeral lengthening has been successfully performed in both antegrade and retrograde fashions<sup>25,26</sup>

Fig. 2

**Fig. 2-A** Radiograph of the left lower limb of a patient with osteogenesis imperfecta who underwent 5 cm of lengthening with use of an intramedullary lengthening nail. **Fig. 2-B** Radiograph of the left lower limb of a patient with previous radiation treatment to the distal part of the femur, which created a partial growth arrest. An acute correction and lengthening was performed with use of a retrograde femoral lengthening nail. **Fig. 2-C** Radiograph of the right lower limb of a patient with fibrous dysplasia who was managed with lengthening of the femur with use of an intramedullary lengthening nail. The lengthening nail will be exchanged for a permanent cephalomedullary nail at full consolidation.

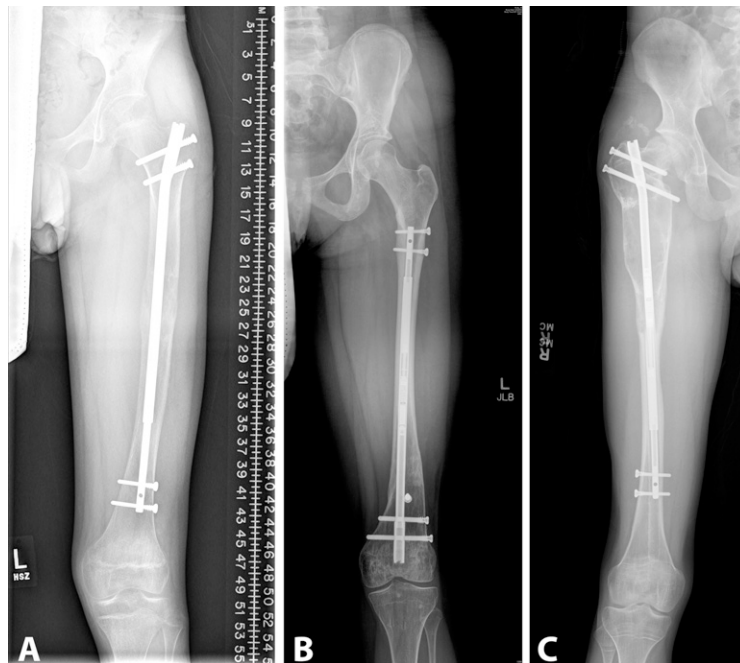

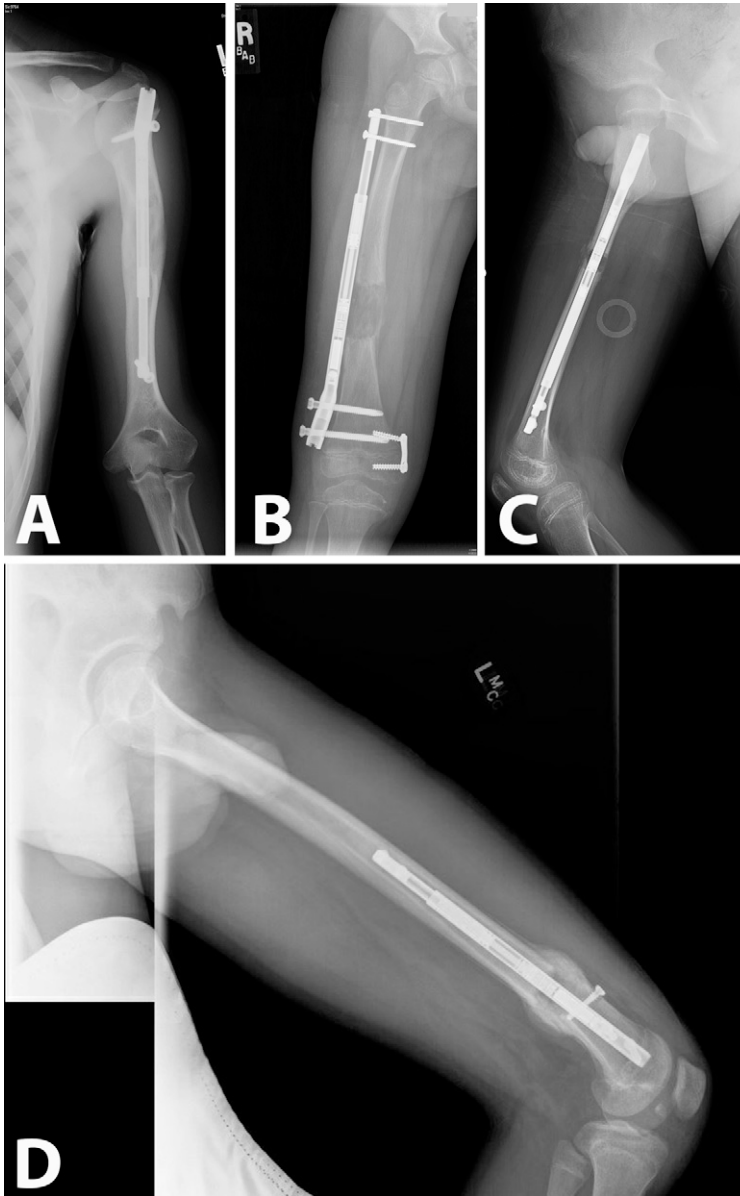


Fig. 3

**Fig. 3-A** Radiograph of the upper limb of a patient in whom a tibial nail was used to lengthen the humerus by 5 cm in an antegrade fashion. **Fig. 3-B** Radiograph of the lower limb of a 4-year-old patient in whom an extramedullary femoral nail was used to lengthen the femur. The nail was tunneled in a submuscular fashion under the lateral soft tissues of the thigh. **Fig. 3-C** Radiograph of the lower limb of a patient in whom the insertion of a “long” femoral nail required an osteotomy at the apex of the sagittal bow to accommodate the straight shape of the nail. This approach prevents excessive reaming of the anterior cortex. **Fig. 3-D** Radiograph of the lower limb of a patient who was managed with a “short” femoral nail that stops before the sagittal bow of the femur is encountered. This approach allows the straight implant to fit in the curved bone without damaging the anterior cortex of the femur.

(Fig. 3-A). However, because of the limited nail sizes, this technique can only be applied to patients with humeri that can accommodate the available lengths and diameters of the nail.

### Valgus Deformity

Because these devices lengthen along the anatomical axis of the femur, the mechanical axis will drift laterally as the lengthening progresses. This process has been estimated to induce a lateral shift of the mechanical axis of approximately 1 mm for every 1 cm of lengthening<sup>27,28</sup>. Therefore, intramedullary lengthening of

the femur will exacerbate any preexisting valgus deformity. For patients with even mild valgus deformity in the femur preoperatively, a varus-producing osteotomy at the time of nail insertion is recommended.

### Patient Size

It is possible for a patient to be either too big or too small for intramedullary limb-lengthening. When a magnetic intramedullary nail is used, the patient needs to have a sufficiently thin soft-tissue envelope to allow the magnet in the nail to communicate with the magnet in

the handheld device that is placed on the skin. If the patient is overweight, the distance between the magnets may become too large for any effective communication between the magnets to occur. This problem is most commonly encountered in the thigh, where large soft-tissue envelopes are being found with increasing prevalence. In some cases, placing the nail in a retrograde rather than antegrade manner will place the magnet in a thinner portion of the limb, which may allow proper communication between the magnets. The other option in large patients is to use a

motorized intramedullary nail, which uses a subcutaneous receiver rather than magnets as its mode of communication. This design eliminates the concern about excessive soft-tissue thickness<sup>9</sup>.

Patients also can be too small for intramedullary lengthening nails if the length of the bone or the diameter of the bone canal cannot accommodate the size of the nail. This problem is most commonly encountered in skeletally immature patients in whom the use of tibial nails and retrograde femoral nails is not feasible (because insertion would violate the physis), leaving trochanteric-entry antegrade femoral nails as the only option. While antegrade nailing has been performed in patients as young as 7 years old, there is concern about injuring the blood supply to the femoral head during the insertion process<sup>29</sup>. For patients who are not candidates for trochanteric-entry antegrade nails, it is possible to use the nails in an extramedullary fashion<sup>30</sup> (Fig. 3-B). While this usage is strictly off-label, it does allow the patient to achieve limb-lengthening without the need for an external fixator. In this case, the nail is tunneled in a submuscular fashion under the lateral aspect of the thigh and is attached to the femur with fully threaded screws proximally and distally. This technique is still evolving and is not meant for large lengthenings; currently, this method is only recommended for lengthenings of 3 to 4 cm<sup>30</sup>.

### Nail Length

Lengthening with intramedullary nails requires the surgeon to pre-plan the procedure several weeks in advance. The pre-planning is important because it provides the surgeon with an opportunity to review the surgical steps and anticipate any difficulties that may be encountered. From a more practical standpoint, the limited inventory of implants requires the surgeon to order the specific length and diameter of the nail from the product representative several weeks in advance. In unusual circumstances, bone deformity or canal

obstructions will dictate the length of bone available for the nail. However, in more routine cases, the surgeon will have the option of using multiple different nail lengths. As the nail houses internal mechanisms that control the nail's ability to distract, the shape of the implant is required to be non-cannulated and straight. Because the medullary canals of the tibia and humerus are also relatively straight in both the coronal and sagittal planes, the introduction of a rigidly straight nail is not an issue in these anatomical locations. However, because the femur usually has an apex-anterior sagittal bow, the surgeon must take this factor into account when attempting to insert a straight nail into a curved bone. There are 2 basic strategies for dealing with this shape mismatch. To avoid reaming out the anterior cortex of the femur, the surgeon can choose to perform the osteoplasty at the apex of the sagittal bow of the femur (Fig. 3-C). This approach will allow the femur to open posteriorly so that the straight nail can pass into a more accommodating femoral shape. However, this strategy forces the surgeon to perform the osteotomy in the diaphyseal portion of the femur, which may not be the surgeon's preferred location. The alternative approach is to use a shorter nail length that avoids the apex of the sagittal femoral bow (Fig. 3-D). This approach is easier when using the retrograde technique (as the bow is further away from the nail starting point), but antegrade passage is possible only in large femora. Regardless of the nail length chosen, it is important to pay attention to the femoral reaming path in the sagittal plane to ensure that the anterior cortex of the femur is not inadvertently erased (Fig. 4-A). This is especially true when rigid reamers are being used to create the nail path. Half-pins or drill-bits can be placed prior to starting the reaming process, which will guide the reamers in the desired path and away from the anterior cortex.

### Guidewire Placement

Most pediatric femoral trauma nails are designed to be inserted into the central

or lateral third of the greater trochanter to maximize their distance from the blood supply to the femoral head. Trochanteric-entry femoral antegrade intramedullary lengthening nails are designed to have a starting point in the medial portion of the greater trochanter. Starting the nail more laterally in the trochanter will induce varus into the proximal femoral segment (Fig. 4-B). Because it is important to keep the initial guidewire as close to the medial portion of the greater trochanter as possible, the surgeon should be careful to avoid inadvertent passes with the sharp tip of the guidewire into the femoral neck region while establishing the starting point. It is helpful to aim laterally with the guidewire on the trochanter at first until the tactile location of the greater trochanter can be established. The guidewire can then be gradually walked along the greater trochanter in a medial direction until the proper starting point is identified.

### Reaming

Manufacturer guidelines for the magnetic nail suggest over-reaming the canal by 2 mm prior to insertion of the magnetic lengthening nail. While the exact amount of over-reaming can be debated, the surgeon should always be able to insert the nail into the canal with minimal force. Appropriate reaming of the canal should allow the surgeon to fully insert the nail by hand without having to use a mallet. Gentle taps with the mallet are occasionally acceptable, but if the nail is not passing easily, additional reaming to enlarge the canal space should be performed. Aggressive insertion with the mallet risks damaging the internal mechanisms of the nail. It is always a good idea to test the nail's function at the end of the procedure to ensure that it is working properly, especially if force was required to insert it.

The motorized nail is designed for a line-to-line fit and does not require as much over-reaming (approximately 1 mm) because rigid reamers are used. This system also utilizes reaming sleeves that are designed to protect the tissues

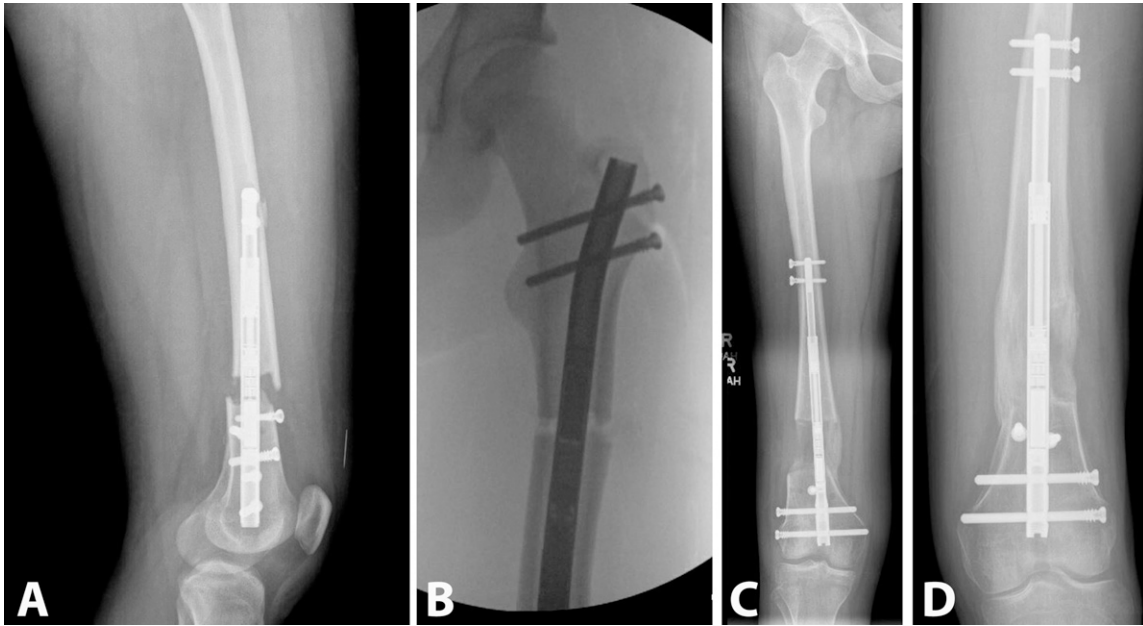


Fig. 4

**Fig. 4-A** Radiograph showing a straight femoral nail encountering the anterior cortex of the femur. A shorter implant or an osteotomy at the level of the bow would have avoided this problem. **Fig. 4-B** Radiograph showing that, if the starting point on the greater trochanter is not medial enough, the proximal femoral segment will be rotated into varus by the implant. **Fig. 4-C** Radiograph of the lower limb of the patient in whom a blocking screw was placed on the lateral side of the nail where the open canal space was present. The distal femoral fragment is now “blocked” from inadvertent movement between the medial cortex on the medial side and the blocking screw on the lateral side of the nail. **Fig. 4-D** Radiograph of the lower limb of a patient in whom the nail position had canal space on both the medial and lateral sides. Blocking screws were placed on both sides of the nail to prevent loss of correction of the distal femoral fragment.

from the reaming process. This is especially important when intra-articular insertion points are required, such as in the retrograde femur or the proximal part of the tibia. The sleeves are designed to prevent the bone spicules generated during reaming from spilling into the joint.

A 1-mm lengthening can be performed intraoperatively to verify that the nail is distracting appropriately and the osteotomy is complete. If there is doubt about the nail’s ability to elongate after 1 mm, then a second 1 mm of lengthening can be added. If 2 mm of distraction are necessary, the nail can subsequently be run in reverse to compress the osteotomy site by 1 mm. Reversal of the entire 2 mm is not recommended as the nail mechanism may become damaged if it is inadvertently overly compressed.

### Blocking Screws

When deformity correction is being combined with gradual distraction in the distal part of the femur or proximal part of the tibia, the liberal use of blocking

screws to maintain the corrected position is critical<sup>31</sup>. Despite the use of 2 interlocking pegs or screws to secure the bone segment, it is still possible for the correction to be lost if there is space in the canal against the cortex while the opposite side of the nail has a large open canal space next to it. In this situation, a blocking screw that is placed directly against the nail on the open canal side of the nail will prevent unwanted movement (Fig. 4-C). The best blocking screw is one that touches the nail during the insertion process. If there is open space in the canal on both sides of the nail when it is in its final position, then a blocking screw will need to be placed on both sides of the nail (Fig. 4-D). This concept is true in both the coronal and sagittal planes. If half-pins or drill-bits are used to guide the reaming process during the procedure, they can be replaced with a blocking screw at the end of the procedure. Either pegs or fully threaded screws can be used for blocking. For fixator-assisted proce-

dures, the incisions used for placement of the half-pins often can be utilized for blocking screw placement to minimize the number of additional incisions.

### Regenerate Formation

The technique of intramedullary limb-lengthening creates regenerate bone that is visually different from the regenerate bone that is produced in association with the use of external fixators. With intramedullary limb-lengthening, the regenerate bone matures from the outside in and has an eggshell appearance<sup>32</sup> (Fig. 5). During consolidation, the walls of the eggshell gradually thicken and solidify. Occasionally, a defect in the regenerate bone can be seen; this typically occurs where the periosteum has sustained an iatrogenic injury during the surgical approach to the bone, such as in the anterior part of the tibia or the lateral part of the femur. The different appearance and maturation of the regenerate bone is likely related to the different mechanical and biological environment surrounding the bone when intramedullary lengthening



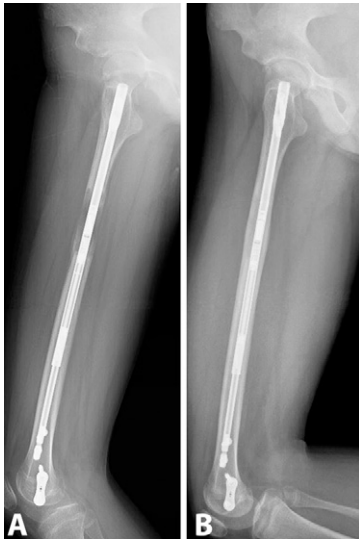

Fig. 5

**Figs. 5-A and 5-B** Radiographs of the lower limb of a patient managed with intramedullary lengthening, illustrating how maturation of the regenerate bone proceeds from the outside in. **Fig. 5-A** Initially, the regenerate bone has an eggshell appearance. **Fig. 5-B** Over time, the cortices develop and thicken.

nails are used. Unlike external fixators that allow axial micromotion, intramedullary nails are axially rigid. In addition, reaming of the bone's endosteal blood supply during the nail-insertion process leaves the periosteum as the primary source of vascular ingrowth. Stretching the periosteal blood supply with acute angular and rotational corrections further stresses the ability to produce regenerate bone<sup>32</sup>. Therefore, an extended latency period

and a slower rate and rhythm of lengthening may be necessary for patients undergoing large acute corrections followed by distraction with an intramedullary nail.

### Tibial Lengthening

Several nuances have been discovered that are unique to intramedullary lengthening tibial nails. First, the normal latency, rate, and rhythm for tibial lengthening with use of an external fixator should be modified when using intramedullary lengthening tibial nails. The latency period needs to be extended by at least several days when the tibia is lengthened with an intramedullary nail. The rate and rhythm also will require downsizing. Lengthening by 0.25 mm 4 times a day will risk producing inadequate regenerate bone. Starting at 0.66 or 0.75 mm per day should be the maximum rate until radiographs demonstrate the formation of healthy regenerate bone<sup>33</sup>. The rate can then be increased if necessary, but vigilant monitoring of the regenerate formation is required in all cases of tibial lengthening. Weekly assessment of tibial bone formation with radiographs is recommended. The rhythm also can be divided into smaller increments if necessary. For example, lengthening by 0.12 mm per session 6 times a day may be a safer way to gain 0.72 mm per day

than lengthening by 0.24 mm per session 3 times a day.

The second nuance involves the level of the osteotomy. The typical desired osteotomy level for distraction osteogenesis is just below the tibial tubercle. In essence, this osteotomy position creates a proximal-third tibial fracture. Because of muscle forces, the proximal fragment is pulled into extension when the knee is hyperflexed in order to allow for reaming and nail insertion. There are several options to prevent creating an apex-anterior deformity during nailing. First, the osteotomy level can be made slightly more distal to avoid the tendency for the proximal fragment to extend. While this makes the nail-insertion process easier, it creates a diaphyseal osteotomy, which may not be the preferable location for regenerate bone formation (Fig. 6-A). This location also will limit the ability to allow any simultaneous metaphyseal angular deformity correction with the nail. Second, the placement of a blocking half-pin or screw in the posterior aspect of the proximal part of the tibia will guide the reamer to stay in the anterior portion of the tibial metaphysis (Fig. 6-B). This will help to mitigate the extension of the proximal fragment. Finally, performing tibial nailing via a suprapatellar approach will allow the knee to remain extended during the nail-insertion process.

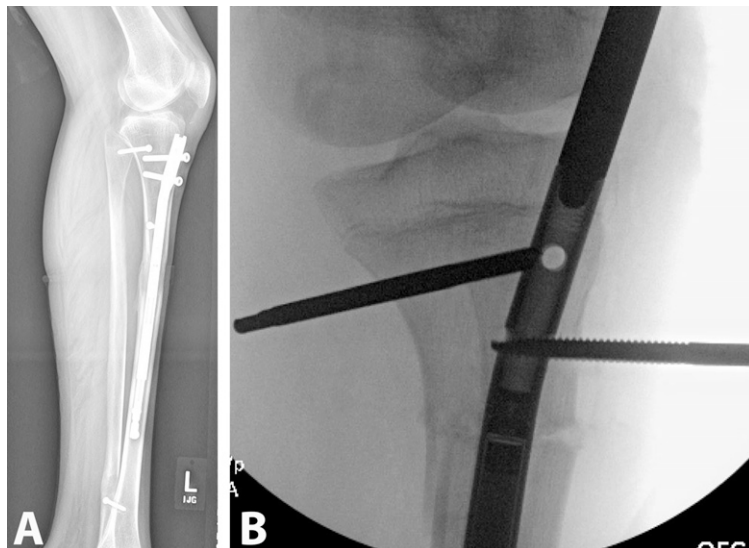


Fig. 6

**Fig. 6-A** A diaphyseal osteotomy of the tibia will prevent the proximal tibial fragment from creating an apex-anterior deformity when the knee is flexed during the reaming and nail-insertion process. **Fig. 6-B** A blocking pin or screw placed in the posterior part of the tibia will keep the reamer in the anterior portion of the proximal part of the tibia and prevent an apex-anterior deformity from occurring.

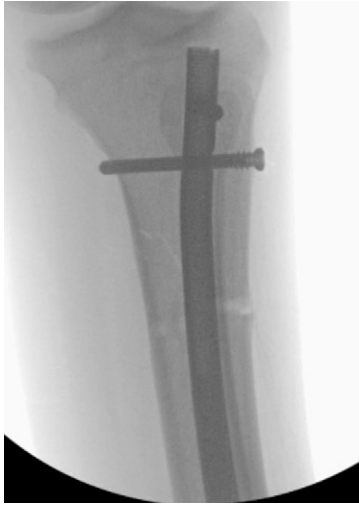

Fig. 7

Radiograph illustrating how it is possible to secure the proximal tibiofibular joint with an interlocking peg when lengthening a left tibia.

Keeping the knee extended prevents the apex-anterior deformity from occurring, but this approach requires special instrumentation to protect the knee joint during reaming and insertion.

The final 4 tibial nuances are smaller details but are still important to the success of the procedure. First, there is a theoretical concern regarding the orientation of the vent holes placed at the tibial osteotomy site prior to reaming. If the vent holes violate the lateral cortex of the tibia, the bone particles that are generated during reaming can enter the anterior compartment, potentially increasing the volume of the compartment. In order to decrease the risk of compartment syndrome, it is recommended that the anterior compartment be released or that the vent holes be arranged to avoid penetrating the lateral tibial cortex. Second, the nail occasionally may be seated so far anteriorly that there is no space for the proximal threads of the peg to engage the near cortex of the tibia. In that case, a fully threaded screw should be substituted for the peg. Third, it is possible to place fixation through the proximal interlocking nail hole as a method to secure the proximal tibiofibular joint in left tibiae. If the nail is inserted and rotated properly, the proximal nail hole can be oriented to overlap the fibular head. Because of the pattern of the proximal holes, this is not currently

possible in right tibiae (Fig. 7). Fourth, as a result of soft-tissue tethering, all tibial lengthenings tend to bend into valgus and apex-anterior directions. In most cases, the use of blocking screws lateral and posterior to the tibial nail will counteract this tendency. However, when the smallest-diameter nail size (8.5 mm) needs to be used, valgus deformation can occur through bending of the nail even with blocking screw placement at the time of insertion (Fig. 8). Exchanging the nail at the completion of lengthening with a trauma nail can resolve this issue. Use of a stainless steel motorized nail instead of a titanium magnetic nail also may prevent this issue from occurring.

### Regenerate Rescue

If, during the distraction phase, new regenerate bone is not visible by the third week after surgery, then there may be an issue with regenerate formation. This situation cannot be ignored because it will only worsen if the lengthening continues unabated. While there may be a number of reasons why the regenerate is not forming properly (poor host biology, a latency period that is too short, a rate and rhythm that are too fast, iatrogenic injury to the bone during osteotomy, etc.), the important step is to recognize that the bone is not forming and to react quickly and appropriately. Hoping that the situation will improve while continuing to lengthen is not a wise choice. At a minimum, the lengthening rate should be slowed immediately; however, completely stopping the lengthening for a week to see if the regenerate bone improves is recommended. If necessary, the nail can be reversed back to its original starting point and a new latency period can be instituted. The lengthening can then be resumed at the appropriate time with a slower rate and rhythm. A lateral radiograph typically provides the best view for judging the health and continuity of the regenerate bone. A smooth, continuous column of bone should be seen from one edge of the osteotomy site to the other (Fig. 6). In any case in which there appears to be a

problem with the production of new bone, a weekly assessment of the regenerate bone is recommended. During the first few weeks of lengthening, when osteoid is not yet visible on a radiograph, an ultrasound image may be helpful to determine whether the distraction gap is patent. If the lengthening has continued despite poor regenerate bone formation, then rescue options include injecting the regenerate with bone-marrow aspirate, autogenous bone-grafting of the regenerate, or reversing the nail and starting over. Exchanging the intramedullary lengthening nail with a standard trauma intramedullary nail is another option. This may require the use of an intraoperative external fixator to maintain the bone length during the exchange process. Both the trauma nail will allow the patient to advance in terms of weight-bearing status and the reaming involved in inserting the nail will potentially help to stimulate new bone formation<sup>34</sup>.

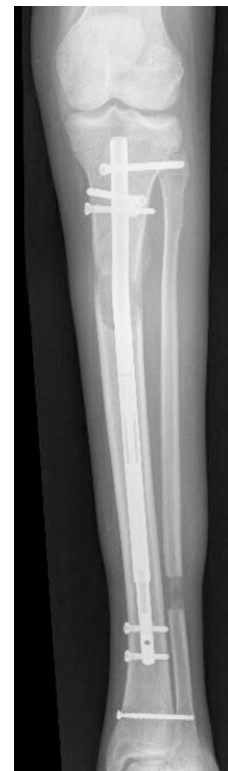

Fig. 8

Radiograph illustrating how, despite blocking screws, the soft-tissue forces bend the tibial lengthening into valgus. Note the bending of the nail within the bone.

### Limb-Lengthening in Patients with Congenital Shortening

Because congenitally short limbs are not genetically designed to be full size, lengthening of these limbs has always been more difficult than that of limbs with shortening due to trauma or physical injury. With external fixation, certain precautions, such as spanning of the joints, could be utilized to minimize the risk of joint subluxation or dislocation during distraction. With intramedullary limb-lengthening, bridging the joint is not possible; therefore, other precautions need to be taken. Consequently, the concept of preparatory surgery in which the limb segment is prepared for lengthening by initially stabilizing the adjacent joints is critical<sup>35</sup>. In the hip, a series of soft-tissue releases are performed in the hip flexors, external rotators, and abductors. In addition, the femoral neck-shaft angle, version, and acetabular coverage need to be normalized. In the knee, ligamentous instability needs to be addressed with ligament reconstruction, and varus or valgus angulation needs to be addressed with guided growth. In the ankle, removal of the fibular anlage combined with tibial shortening to place the foot and ankle in neutral alignment may be necessary<sup>36</sup>. Placement of a temporary extra-articular tibioalcalneal screw also can be utilized to hold the ankle in neutral during the lengthening<sup>37</sup>. Once the joints are stabilized, intramedullary limb-lengthening can then be attempted. Even if the joints are stable, it is important to assess the range of motion of each joint. It should be remembered that lengthening will only make tight muscles tighter. Therefore, fractional lengthening of the hip flexors, hamstrings, or gastrocnemius-soleus complex muscles may be necessary at the time of nail insertion. For femoral lengthenings, if the iliotibial band has not already been utilized for a prior knee ligament reconstruction, it should be released as part of the nail-insertion process. Once the lengthening commences, it is critically important to examine the range of motion at each visit. Full knee extension with flexion

to 60° to 90° at all times is ideal. If the motion starts to decrease in either direction, then the surgeon should strongly consider slowing or stopping the lengthening until normal motion has been reestablished. To help maintain knee extension, a dynamic knee-extension brace is recommended for each patient. This brace is ordered preoperatively so that it can be applied in the operating room at the end of the procedure. The brace should be used at night and during the day whenever the patient is recumbent. A solid ankle-foot orthosis should be used in patients undergoing tibial lengthening to resist the formation of an equinus contracture. Formal physical therapy at least once a week to monitor and reinforce the range-of-motion exercises is important. The patient should be taught a daily routine of exercises to perform 7 days a week. In addition, starting the lengthening at a slower rate (0.75 mm/day) in patients with congenital shortening is recommended as it will place less daily stress on the soft tissues.

It is also vital to assess the radiographic findings at each weekly visit. While it is natural for the eye to be drawn to analyze the health of the regenerate bone on radiographs, it is equally important to assess the joint alignment, especially on the lateral view of the knee, at each visit. The first hint of joint subluxation should alert the surgeon to consider slowing or stopping the lengthening immediately. Ignoring the finding and continuing the lengthening will only make the situation worse. Either increasing the number of formal physical therapy sessions per week or admitting the patient for daily therapy are potential options at first. If sufficient improvement is not seen from therapy alone, custom braces can be used to augment the rescue process<sup>38</sup>. If all else fails, surgical release of the contracted muscles, reversal of the lengthening, or external fixation to restore the joint needs to be performed.

Two final points must be made about patients with congenital shortening. First, it is important for the surgeon to have

modest goals and not to let the patient or the family persuade the surgeon to continue lengthening when there are signs of soft-tissue limitation. Multiple small, safe lengthenings are better than attempting one heroic lengthening that damages the function of a joint. Creating a new problem such as knee subluxation is not worth a few extra millimeters of length. Second, many patients with congenital shortening have had previous lengthenings with external fixators. There is a risk that previous pin sites may contain latent bacteria that could potentially infect the site of the intramedullary device. While the risk of intramedullary infection is low, it is important to discuss this factor with the patient and family preoperatively. If there is any concern, STIR MRI (short-tau inversion recovery magnetic resonance imaging) should be ordered before surgery to evaluate the pin sites<sup>39</sup>.

### Pain Management

Lengthening with an intramedullary nail should be a comfortable process for the patient. In contrast to patients undergoing lengthening with an external fixator, patients undergoing lengthening with an intramedullary nail should not require pain medication for the majority of the postoperative treatment course. In most cases, the patient may experience a short period of initial surgical pain related to the insertion of the device but will then rapidly transition to the use of non-narcotic pain medication. Occasionally, a muscle relaxer is required for patients experiencing muscle spasms related to the distraction phase, but this is not routine.

Because the patient is expected to be comfortable during the distraction phase, any reported discomfort is usually a signal that something may be wrong. A thorough review of the status of the implants, regenerate bone formation, and joint alignment on the radiographs should be undertaken immediately. Pain can be the first indication that the soft-tissue envelope is reaching its stretchable limit and warrants a thorough physical examination of the joint range of motion. Pain also can signify that a premature



consolidation is forming. If the range of motion and joint alignment are normal and there is no sign of premature consolidation or an incomplete osteotomy, then discomfort can sometimes be reduced by decreasing the size of the lengthening increments. For example, if the lengthening is being performed at an increment of 0.25 mm per session 4 times per day, decreasing the increment to 0.12 mm per session but increasing the number of sessions to 8 times a day will achieve the same daily length but in a more gentle manner.

### Nail Removal

It is generally recommended that every intramedullary lengthening nail should be removed from the patient once the healing of the regenerate bone is completed as there are concerns regarding leaving an implant that contains machinery and/or a rare earth magnet inside a patient permanently<sup>40</sup>. Because these devices are not familiar to all surgeons, there is also a practical issue that removal could be difficult if it becomes necessary in the future. Consequently, most nails are removed 9 to 12 months after insertion as an outpatient procedure. The surgeon can help to make the removal process easier by (1) leaving the interlocking pegs or screws slightly proud at the near cortex to make them easier to find and remove later, especially when employing percutaneous techniques, and (2) avoiding the use of an end cap on the nail. Although the nail system offers an end cap, routine placement is not necessary as there is usually no issue with accessing the threads of the nail. In addition, attempting to remove the end cap can be frustrating and adds morbidity to the procedure.

An alternative strategy is to remove the nail while the regenerate is still consolidating and replace it with a trauma nail. This strategy has several advantages: the patient can begin fully weight-bearing faster with a trauma nail in place, the healing of the regenerate may be enhanced by reaming during the nail exchange, and the regenerate bone will be protected over the patient's entire lifetime as the trauma nail does not need to be removed<sup>34</sup>. One

caveat to this technique is that the surgeon will need to employ a temporary external fixator at the time of nail exchange to maintain length and alignment.

There has also been concern related to the use of MRI for patients undergoing intramedullary limb-lengthening with a magnetic nail—specifically, that the magnetic field from the MRI could cause the implant to migrate, involuntarily elongate, or overheat inside the patient. However, a recent study demonstrated that there was no evidence of involuntary distraction or increase in temperature when the implant was exposed to a 1.5 or 3.0-T magnet<sup>39</sup>. However, the authors did find that there was a decrease in the internal distracting force after exposure to a 3.0-T magnet and recommend avoiding any MRI using a 3-T magnet in patients who are still actively undergoing limb-lengthening. They did not find any effect on distracting force in the 1.5-T magnet.

In summary, removal of an intramedullary lengthening nail has been the routine for all patients given the previous concerns about MRI and the internal mechanisms within the device. With the new information regarding MRI safety, the surgeon may consider having a discussion about leaving the implants in place with some adult patients who do not wish to undergo another procedure to remove the nail. Additional information about these techniques can be obtained by contacting the Limb Lengthening and Reconstruction Society of North America at [LLRS.org](http://LLRS.org).

Christopher A. Iobst, MD<sup>1</sup>

<sup>1</sup>Department of Orthopedic Surgery, Nationwide Children's Hospital, Columbus, Ohio

E-mail address: [christopher.iobst@nationwidechildrens.org](mailto:christopher.iobst@nationwidechildrens.org)

ORCID iD for C.A. Iobst: [0000-0002-0329-5321](https://orcid.org/0000-0002-0329-5321)

### References

1. Guichet JM, Deromedis B, Donnan LT, Peretti G, Lascombes P, Bado F. Gradual femoral lengthening with the Albizzia intramedullary

nail. *J Bone Joint Surg Am.* 2003 May;85(5):838-48.

2. Burghardt RD, Herzenberg JE, Specht SC, Paley D. Mechanical failure of the Intramedullary Skeletal Kinetic Distractor in limb lengthening. *J Bone Joint Surg Br.* 2011 May;93(5):639-43.

3. Kenaway M, Krettek C, Liodakis E, Wiebking U, Hankemeier S. Leg lengthening using Intramedullary Skeletal Kinetic Distractor: results of 57 consecutive applications. *Injury.* 2011 Feb;42(2):150-5.

4. Kenaway M, Krettek C, Liodakis E, Meller R, Hankemeier S. Insufficient bone regenerate after intramedullary femoral lengthening: risk factors and classification system. *Clin Orthop Relat Res.* 2011 Jan;469(1):264-73. Epub 2010 Apr 2.

5. Wang K, Edwards E. Intramedullary Skeletal Kinetic Distractor in the treatment of leg length discrepancy—a review of 16 cases and analysis of complications. *J Orthop Trauma.* 2012 Sep;26(9):e138-44.

6. Lee DH, Ryu KJ, Song HR, Han SH. Complications of the Intramedullary Skeletal Kinetic Distractor (ISKD) in distraction osteogenesis. *Clin Orthop Relat Res.* 2014 Dec;472(12):3852-9.

7. Kirane YM, Fragomen AT, Rozbruch SR. Precision of the PRECICE internal bone lengthening nail. *Clin Orthop Relat Res.* 2014 Dec;472(12):3869-78.

8. Paley D, Harris M, Debiparshad K, Prince D. Limb lengthening by implantable limb lengthening devices. *Tech Orthop.* 2014 Jun;29(2):72-85.

9. Baumgart R, Betz A, Schweiberer L. A fully implantable motorized intramedullary nail for limb lengthening and bone transport. *Clin Orthop Relat Res.* 1997 Oct;(343):135-43.

10. Singh S, Lahiri A, Iqbal M. The results of limb lengthening by callus distraction using an extending intramedullary nail (Fitbone) in non-traumatic disorders. *J Bone Joint Surg Br.* 2006 Jul;88(7):938-42.

11. Krieg AH, Lenze U, Speth BM, Hasler CC. Intramedullary leg lengthening with a motorized nail. *Acta Orthop.* 2011 Jun;82(3):344-50. Epub 2011 May 11.

12. Dincürek H, Kocaoglu M, Eralp IL, Bilen FE, Dikmen G, Eren I. Functional results of lower extremity lengthening by motorized intramedullary nails. *Acta Orthop Traumatol Turc.* 2012;46(1):42-9.

13. Landge V, Shabtai L, Gesheff M, Specht SC, Herzenberg JE. Patient satisfaction after limb lengthening with internal and external devices. *J Surg Orthop Adv.* 2015 Fall;24(3):174-9.

14. Szymczuk VL, Hammouda AI, Gesheff MG, Standard SC, Herzenberg JE. Lengthening with monolateral external fixation versus magnetically motorized intramedullary nail in congenital femoral deficiency. *J Pediatr Orthop.* 2017 Jun 25. Epub 2017 Jun 25.

15. Kocaoglu M, Bilen FE. Fixator-assisted nailing for correction of long bone deformities. *Oper Tech Orthop.* 2011 Jun;21(2):163-73.

16. Horn J, Hvid I, Huhnstock S, Breen AB, Steen H. Limb lengthening and deformity correction with externally controlled motorized intramedullary nails: evaluation of 50 consecutive lengthenings. *Acta Orthop.* 2019 Feb;90(1):81-7. Epub 2018 Oct 29.

- 17.** Fragomen AT, Rozbruch SR. Lengthening and deformity correction about the knee using a magnetic internal lengthening nail. *SICOT J.* 2017;3:25. Epub 2017 Mar 22.
- 18.** Iobst CA, Rozbruch SR, Nelson S, Fragomen A. Simultaneous acute femoral deformity correction and gradual limb lengthening using a retrograde femoral nail: technique and clinical results. *J Am Acad Orthop Surg.* 2018 Apr 1;26(7):241-50.
- 19.** Baumgart R. The reverse planning method for lengthening of the lower limb using a straight intramedullary nail with or without deformity correction. A new method. *Oper Orthop Traumatol.* 2009 Jun;21(2):221-33.
- 20.** Muratori F, Scocciati G, Beltrami G, Matera D, Capanna R, Campanacci DA. Is an intramedullary nail a valid treatment for limb-length discrepancy after bone tumor resection? Case descriptions. *Surg Technol Int.* 2018 Nov 11;33:281-8.
- 21.** Cashin M, Coombs C, Torode I. A-frame free vascularized fibular graft and femoral lengthening for osteosarcoma pediatric patients. *J Pediatr Orthop.* 2018 Feb;38(2):e83-90.
- 22.** Acan AE, Basci O, Havitcioglu H. Aneurysmal bone cyst healing response with intramedullary lengthening nail. *Acta Orthop Traumatol Turc.* 2018 May;52(3):232-5. Epub 2017 May 18.
- 23.** Baumgart R, Bürklein D, Hinterwimmer S, Thaller P, Mutschler W. The management of leg-length discrepancy in Ollier's disease with a fully implantable lengthening nail. *J Bone Joint Surg Br.* 2005 Jul;87(7):1000-4.
- 24.** Karakoyun O, Sokucu S, Erol MF, Kucukkaya M, Kabukçuoğlu YS. Use of a magnetic bone nail for lengthening of the femur and tibia. *J Orthop Surg (Hong Kong).* 2016 Dec;24(3):374-8.
- 25.** Hammouda AI, Standard SC, Robert Rozbruch S, Herzenberg JE. Humeral lengthening with the PRECICE magnetic lengthening nail. *HSS J.* 2017 Oct;13(3):217-23. Epub 2017 Apr 21.
- 26.** Kurtz AM, Rozbruch SR. Humerus lengthening with the PRECICE internal lengthening nail. *J Pediatr Orthop.* 2017 Jun;37(4):e296-300.
- 27.** Burghardt RD, Herzenberg JE, Burghardt MH. Trigonometric analysis of the mechanical axis deviation induced by telescopic intramedullary femoral lengthening nails. *J Appl Biomech.* 2011 Nov;27(4):385-91. Epub 2011 Aug 26.
- 28.** Burghardt RD, Paley D, Specht SC, Herzenberg JE. The effect on mechanical axis deviation of femoral lengthening with an intramedullary telescopic nail. *J Bone Joint Surg Br.* 2012 Sep;94(9):1241-5.
- 29.** Hammouda AI, Jauregui JJ, Gesheff MG, Standard SC, Herzenberg JE. Trochanteric entry for femoral lengthening nails in children: is it safe? *J Pediatr Orthop.* 2017 Jun;37(4):258-64.
- 30.** Dahl MT, Georgiadis A, Laine J, Novotny S. Extramedullary motorized lengthening of the femur in pediatric patients. Read at the Annual Meeting of POSNA Scientific Program; 2019 May 17; Charlotte, NC. Paper no. 99.
- 31.** Muthusamy S, Rozbruch SR, Fragomen AT. The use of blocking screws with internal lengthening nail and reverse rule of thumb for blocking screws in limb lengthening and deformity correction surgery. *Strateg Trauma Limb Reconstr.* 2016 Nov;11(3):199-205. Epub 2016 Sep 24.
- 32.** Green SA, Dahl MT. Intramedullary limb lengthening. Principles and practice. Springer; 2018. p 17-22.
- 33.** Schiedel FM, Vogt B, Tretow HL, Schuhknecht B, Gosheger G, Horter MJ, Rödl R. How precise is the PRECICE compared to the ISKD in intramedullary limb lengthening? Reliability and safety in 26 procedures. *Acta Orthop.* 2014 Jun;85(3):293-8. Epub 2014 Apr 23.
- 34.** Rozbruch SR, Kleinman D, Fragomen AT, Ilizarov S. Limb lengthening and then insertion of an intramedullary nail: a case-matched comparison. *Clin Orthop Relat Res.* 2008 Dec;466(12):2923-32. Epub 2008 Sep 18.
- 35.** Paley D, Guardo F. Lengthening reconstruction surgery for congenital femoral deficiency. In: Kocaoglu M, Tsuchiya H, Eralp L, editors. *Advanced techniques in limb reconstruction surgery.* Springer; 2015. p 245-300.
- 36.** Paley D. Surgical reconstruction for fibular hemimelia. *J Child Orthop.* 2016 Dec;10(6):557-83. Epub 2016 Dec 1.
- 37.** Belthur MV, Paley D, Jindal G, Burghardt RD, Specht SC, Herzenberg JE. Tibial lengthening: extraarticular calcaneotibial screw to prevent ankle equinus. *Clin Orthop Relat Res.* 2008 Dec;466(12):3003-10. Epub 2008 Sep 18.
- 38.** Bhav A, Shabtai L, Ong PH, Standard SC, Paley D, Herzenberg JE. Custom knee device for knee contractures after internal femoral lengthening. *Orthopedics.* 2015 Jul 1;38(7):e567-72.
- 39.** Green CJ, Standard SC, Conway JD, Herzenberg JE. Infection during motorized internal lengthening. Read at the Annual Meeting of ILLRS Congress; 2015 Nov 5; Miami, FL. Paper no. 78.
- 40.** Gomez C, Nelson S, Speirs J, Barnes S. Magnetic intramedullary lengthening nails and MRI compatibility. *J Pediatr Orthop.* 2018 Nov/Dec;38(10):e584-7.